


PATIENT

Dog 66418A

PRESENTING CLINICAL SIGNS

History: Grade 3/6 heart murmur. Sedated with Torb and Midaz.

SPECIES

Canine

BREED

Pitbull Mix

SEX

Female Intact

ECHOCARDIOGRAM FINDINGS

2D, m-mode, color flow and doppler imaging is available. Normal mitral valve leaflets with no obvious prolapse into the left atrial lumen. No obvious mitral regurgitation. Normal left atrial dimension. Normal LV diameter with normal myocardial function. The LV wall appears normal. The tricuspid valve appears mildly elongated with trace insufficiency seen. Mild right atrial dilation. Significant right ventricular hypertrophy and remodeling indicative of pressure overload. Right ventricular dilation. Pulmonic outflow velocities are significantly elevated. The pulmonic valve appears severely thickened, tethered and stenotic. There is significant post-stenotic dilation of the main pulmonary artery and branches. Trace pulmonic insufficiency. The aortic valve appears to have normal morphology and mobility. No obvious cardiac shunts are present. No pericardial or pleural effusion noted.

AGE

6 months

WEIGHT

NP

INTERPRETED BY

 Maggie Machen Lamy,
 DVM, DACVIM
 (Cardiology)

IMAGING PERFORMED BY

A. Nicastro, DVM

HOSPITAL NAME

 Charleston Animal
 Society

REFERRING VET

Dr. Fuller

INVOICE

32165

DATE

8/4/23

CARDIAC CHART

CANINE CARDIAC PARAMETERS	MR VMAX (m/s)	TR VMAX (m/s)	LA/AO (Boon method)	LA/AO (Heart Base; Swe)	FS (%)	EF (%)	EPSS (cm)
NORMAL PARAMETER	4.5-5.5	<2.7	1.3	<1.6	28-40	40-100	<0.6
PATIENT	NA	NA	NM	1.1	50	92	NM
CANINE CARDIAC PARAMETERS	HR (BPM)	AV VMAX (m/s)	PV MAX (m/s)	BODY WEIGHT (kg)	LA 2D short axis Base view (cm)	LVIDd Avg; 2D and m-mode short axis (cm)	LVIDs Avg; 2D and m-mode short axis (cm)
NORMAL PARAMETER	50-100	0.7-1.7	0.7-1.6	BELOW	BELOW	BELOW	BELOW
PATIENT	NM	1.3	5.3	NP	2.0	3.0	1.5
*Normal chamber parameters expressed as a mean value (SD)				3	1.27 (5.3)	2.46 (2.46)	1.36 (5.5)
BODY WEIGHT DEPENDENT PARAMETERS				5	1.40 (4.5)	2.74 (5.2)	1.60 (4.7)
*Note: All measurements based upon multi-modal images and methods. An average value is reported.				10	1.50 (3.8)	3.27 (3.5)	2.06 (3.1)
				15	1.83 (2.0)	3.71 (2.4)	2.43 (2.1)
				20	2.02 (1.9)	4.14 (2.2)	2.80 (2.0)
				25	2.18 (2.4)	4.48 (2.9)	3.10 (2.5)
				30	2.33 (3.3)	4.83 (3.9)	3.39 (3.4)
				35	2.48 (4.3)	5.17 (5.0)	3.69 (4.5)
				40	2.62 (5.2)	5.48 (6.1)	3.96 (5.4)
				50	2.88 (7.1)	6.07 (8.3)	4.46 (7.4)

INTERPRETATION OF THE FINDINGS & FURTHER RECOMMENDATIONS

The cause of the murmur is severe valvular pulmonic stenosis. The degree of obstruction is severe based upon the velocity/pressure gradient across the pulmonic valve and the secondary hypertrophy and remodeling of the right ventricle. There is mild RA dilation and trace TR with mild tricuspid valve thickening (likely dysplasia). The risk for CHF in the future is elevated and will likely limit lifespan. No other congenital abnormalities were visualized, however small shunts or defects can be difficult to identify without a sedated bubble study in patients this young.



PATIENT

Dog 66418A

SPECIES

Canine

BREED

Pitbull Mix

SEX

Female Intact

AGE

6 months

WEIGHT

NP

INTERPRETED BY

Maggie Machen Lamy,
DVM, DACVIM
(Cardiology)

IMAGING PERFORMED BY

A. Nicastro, DVM

HOSPITAL NAME

Charleston Animal
Society

REFERRING VET

Dr. Fuller

INVOICE

32165

DATE

8/4/23

Referral for balloon valvuloplasty should be considered in this patient as the gold standard therapeutic option for this condition and may improve long term outcome and delay onset of clinical signs (including exertional syncope and right-sided congestive heart failure). If surgery is not elected, this patient's condition will likely limit lifespan, with many severe PS cases developing CHF by mid-life. Regardless, medical management with atenolol is recommended to decrease heart rate and lessen the obstruction as below. Monitor for development of associated clinical signs (collapse, abdominal distention, cough, labored breathing). **Mild exercise restriction is advised.**

Breeding this animal is not advised due to the genetic link of this disease.

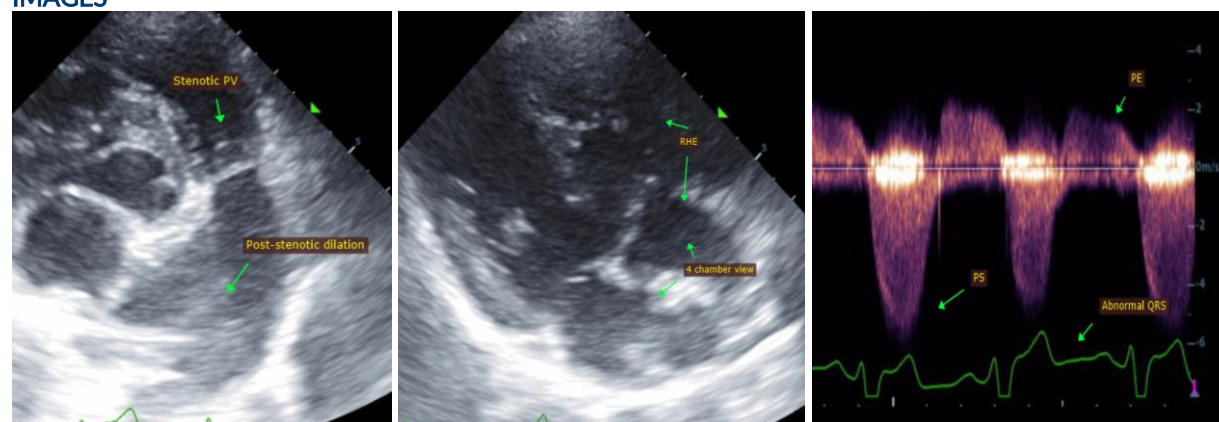
Anesthetic risk is mild to moderate at this time. **Avoid heart rate stimulating drugs such as atropine or glycopyrrolate unless absolutely necessary.** Avoid vasodilators such as acepromazine. Mild IV fluid restriction is advised. Cardiac protective drug choices (opioid/benzodiazepine premedication, propofol or alfaxalone induction, isoflurane gas) are recommended. Pre-oxygenate for 5-10 minutes prior to induction and recover in O₂ if possible. Monitor for arrhythmias, hypotension, and hypoxia both intra and post-operatively and intervene as necessary.

PLAN

Institute atenolol to effect: 25mg tabs, ¼ tab PO BID to start (up-titrate to desired effect). Goal is to suppress heart rate <120-140bpm even with stress/activity. Baseline chest radiographs and ECG are recommended. Referral for balloon valvuloplasty ASAP if desired.

If surgery is declined, recommend recheck echocardiogram in 6 months to assess for progression, response to medication.

IMAGES





PATIENT

Dog 66418A

The information and recommendations provided are based on the images presented by the referring veterinarian. No evaluation can be communicated regarding pathology that was not visible in the image/video clips provided.

SPECIES

Canine

Thank you for this referral. This report was generated using transcription software, and minor dictation errors may be present. If the clinical or image interpretation does not parallel your findings or if I can be of any further assistance, please contact me.

BREED

Pitbull Mix

Maggie Machen Lamy, DVM
Diplomate of the American College of Veterinary Internal Medicine (Cardiology)
info@sonopath.com

SEX

Female Intact

AGE

6 months

WEIGHT

NP

INTERPRETED BY

Maggie Machen Lamy,
DVM, DACVIM
(Cardiology)

**IMAGING
PERFORMED BY**

A. Nicastro, DVM

HOSPITAL NAME

Charleston Animal
Society

REFERRING VET

Dr. Fuller

INVOICE

32165

DATE

8/4/23